

# Management of Sub-ungual Glomus Tumor of the Finger Tips

Nakul Kumar Datta<sup>1, \*</sup>, Ashraful Islam<sup>1</sup>, Palash Kumar Aish<sup>1</sup>, Monisha Datta<sup>2</sup>,  
Suvendu Kumar Banik<sup>2</sup>

<sup>1</sup>Department of Orthopaedic Surgery, Bangabandhu Sheikh Mujib Medical University, Dhaka, Bangladesh

<sup>2</sup>Anwer Khan Modern Medical College, Dhanmondi, Dhaka, Bangladesh

## Email address:

[nkdatta123@yahoo.com](mailto:nkdatta123@yahoo.com) (N. K. Datta)

\*Corresponding author

## To cite this article:

Nakul Kumar Datta, Ashraful Islam, Palash Kumar Aish, Monisha Datta, Suvendu Kumar Banik. Management of Sub-ungual Glomus Tumor of the Finger Tips. *Advances in Surgical Sciences*. Vol. 9, No. 1, 2021, pp. 10-14. doi: 10.11648/j.ass.20210901.13

Received: May 3, 2021; Accepted: May 20, 2021; Published: May 27, 2021

---

**Abstract:** *Background:* Glomus tumors present as painful lesions especially in colder weather, most commonly at finger tips. Glomus tumors are hamartomas that account for 1% to 5% of all soft tissue tumors of the hand. These tumors are usually benign. High-resolution magnetizing resonance imaging (HR-MRI) is useful in the diagnosis of patients with subungual glomus tumor, excellent diagnostic information in detecting the occult lesion. *Objective:* present study was aimed at delineating common presentation and long term treatment outcome. *Materials & methods:* This prospective study was done from January 2004 to July 2019. We found 30 patients diagnosed as having sub-ungual glomus tumors in finger tips and thumb over 15 years period and which were operated in hand unit in the Department of orthopaedic surgery, Bangabandhu Sheikh Mujib Medical University (BSMMU) Dhaka, Bangladesh. The data were collected included demographics, presenting symptoms, duration, physical examination, treatment and recurrence. *Results:* The mean duration of symptoms before presentation was 3.2 years (range 6 months to 15 yrs) Mean age at presentation was 33.7 years (range 20 to 65 yrs.) and female to male ratio 20:10. Thirteen (13) patients had left hand involvement among them ring finger were 06, index finger were 04, middle finger were 02, and thumb 1 and 17 patients had right hand involvement among them ring finger were 06, index finger were 05, middle finger were 03 and little finger were 03. Clinical and radiological assessment were made preoperatively. All the lesions involved the sub-ungual region. The mean size of the lesion was 3.5 mm (range 2.5 to 10mm). All the patients confirmed by histopathological examination. No recurrence in this study and nail change were 03. Transungual approach to be simple procedure which can reduce the chances of recurrence by allowing examination of entire sub-ungual region. Nail deformities are minimal if adequate care is taken during surgery. *Conclusion:* The diagnosis of glomus tumor is largely clinical but HR-MRI is also helpful in diagnosis of patient with sub-ungual glomus tumor. Complete surgical excision offers the only prospect of complete cure. Early diagnosis of glomus tumor is important to avoid lengthy treatment delays.

**Keywords:** Glomus Tumor, Sub-ungual, Finger Tips

---

## 1. Introduction

Glomus tumors are neoplasm of normal glomus body. These are rare tumors and may affect any area of the body, up to 75% occur in hand and approximately 65% of these are in the finger tips particularly in sub-ungual location [1, 2], though pulp lesions are also been reported [3-5]. Normal Glomus bodies are thought to aid in the regulation of skin circulation and highly concentrated in the finger

tips particularly beneath the nail. Solitary glomus tumor usually present as painful locations. Multiple lesions may be painless [1, 6]. They classically present with a triad of symptoms which include pain, pinpoint tenderness and hypersensitivity to cold. This presentation is presented to enable a clinical diagnosis in 90% of cases [6-9], patients usually report a long duration of symptom before correct diagnosis and treatment. They are difficult to diagnosis particularly as they are often small and situated deep in finger tip. Non specific symptoms and unremarkable

physical examination mean that incorrect diagnosis and inappropriate treatments are common place [2-6, 10]. We diagnosed the patients of glomus tumor at sub-ungual area of finger using high-resolution magnetic resonance imaging (HR-MRI) and treated the patients with surgical excision. We present our experience with the management of 30 cases of glomus tumors at the finger tips treated over a period of 15 years.

## 2. Materials and Methods

This prospective case study had been carried out in hand unit in the department of orthopedics, Bangabandhu Sheikh Mujib Medical university (BSMMU) Dhaka, Bangladesh from January 2004 to July 2019. Total 30 patients diagnosed as having glomus tumor at finger tips and thumb over 15 years period. The data collected included demographics, presenting symptoms, duration, physical examination, treatment and recurrence. The complaints of all patients were excruciating pain on touching and with exposure of coldness in the finger tip. The clinical criteria used to make the diagnosis were classical triad of findings: localized tenderness, pain and cold sensitivity. High resolution magnetic resonance imaging is useful in the diagnosis of patients with subungual glomus tumor and all patients were treated by surgical excision and biopsy.

All cases were performed as day cases. One dose of intravenous antibiotic was administered prophylactically about 30 minutes prior to the procedure. After preparing and draping the lesion was localized on table before administration of anesthesia. All operations were performed under loupe-magnification, under regional block anesthesia and under tourniquet control.

Subungual lesions of glomus tumors were excised through a transungual approach (Figure 1a & 1b) over the suspected

site. All specimens were sent for histopathological examination. Sutures were removed at 7<sup>th</sup> post operative day. Subsequent follow up was at 6 to 8 weeks and at 6 months. Patients were advised to return if they experienced any recurrence of symptoms and post operative nail plate deformity.

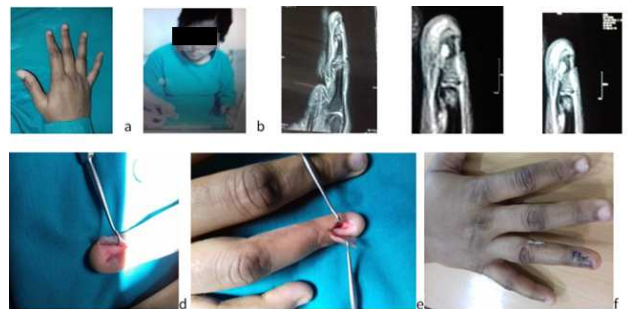
## 3. Results

Of the 30 patients included in the study among them female were 20 and male were 10. The mean duration of symptoms before presentation was 3.2 years (range 6 months to 10 yrs). Mean age at presentation was 33.7 years (range 20 to 65 yrs.) and female to male ratio 19:11. Thirteen (13) patients had left hand involvement among them ring finger were 06, index finger were 04, middle finger were 02, and thumb 1 and 17 patients had right hand involvement among them ring finger were 06, index finger were 05, middle finger were 03 and little finger were 03. Clinical and radiological assessment were made preoperatively. All the lesions involved the subungual region. The mean size of the lesion was 3.5 mm (range 2.5 to 10mm). All the patients confirmed by histopathological examination. No recurrence in this study and nail change were 03. Transungual approach to be simple procedure which can reduce the chances of recurrence by allowing examination of entire subungual region. Nail deformities are minimal if adequate care is taken during surgery. Detailed of the patients are summarized in Table 1. MRI was done in all the cases showed the findings of low signal intensity on T1 weighted image and marked hypersensitivity on T2 weighted image. Prolonged post operative follow up was done for all cases. Post operative follow up which was minimum of 6 months (range 6 months to 10 years)

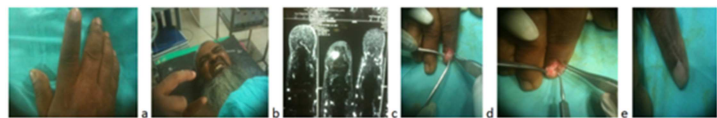
**Table 1.** Distribution of 30 glomus tumor according to age, sex, side, digit, location, duration before presentation.

| Case no | Age (year) | sex | side  | Digit  | location  | Duration before presentation | Size | Treatment | Result        |
|---------|------------|-----|-------|--------|-----------|------------------------------|------|-----------|---------------|
| 1       | 65         | M   | Left  | Ring   | subungual | 8yrs                         | 10mm | Excision  | Pain relieved |
| 2       | 42         | F   | Left  | Ring   | subungual | 2yrs                         | 3mm  | Excision  | Pain relieved |
| 3       | 45         | F   | left  | Ring   | subungual | 3yrs                         | 3mm  | Excision  | Pain relieved |
| 4       | 30         | F   | Right | Little | subungual | 5yrs                         | 4mm  | Excision  | Pain relieved |
| 5       | 25         | F   | Right | Ring   | subungual | 3yrs                         | 4mm  | Excision  | Pain relieved |
| 6       | 50         | M   | Right | index  | subungual | 5yrs                         | 5mm  | Excision  | Pain relieved |
| 7       | 20         | F   | Right | index  | subungual | 6 month                      | 6mm  | Excision  | Pain relieved |
| 8       | 40         | F   | Right | Index  | subungual | 4yrs                         | 3mm  | Excision  | Pain relieved |
| 9       | 36         | F   | Left  | Middle | subungual | 3 yrs                        | 5mm  | Excision  | Pain relieved |
| 10      | 22         | F   | Right | Index  | subungual | 2 yrs                        | 4mm  | Excision  | Pain relieved |
| 11      | 24         | F   | Right | Thumb  | subungual | 3yrs                         | 4mm  | Excision  | Pain relieved |
| 12      | 36         | F   | left  | Middle | subungual | 4yrs                         | 4mm  | Excision  | Pain relieved |
| 13      | 40         | F   | Right | Ring   | subungual | 4yrs                         | 3mm  | Excision  | Pain relieved |
| 14      | 40         | M   | Right | Ring   | subungual | 3 yrs                        | 3mm  | Excision  | Pain relieved |
| 15      | 36         | M   | left  | Index  | subungual | 3yrs                         | 4mm  | Excision  | Pain relieved |
| 16      | 25         | F   | Right | Ring   | subungual | 4yrs                         | 4mm  | Excision  | Pain relieved |
| 17      | 45         | M   | Left  | Ring   | subungual | 5 yrs                        | 5mm  | Excision  | Pain relieved |
| 18      | 30         | M   | Right | little | subungual | 2yrs                         | 4mm  | Excision  | Pain relieved |
| 19      | 42         | F   | Left  | Ring   | subungual | 3yrs                         | 3mm  | Excision  | Pain relieved |
| 20      | 40         | M   | Left  | Index  | subungual | 2yrs                         | 3mm  | Excision  | Pain relieved |
| 21      | 25         | M   | Right | Middle | subungual | 3yrs                         | 4mm  | Excision  | Pain relieved |
| 22      | 41         | F   | Left  | Ring   | subungual | 5 yrs                        | 3mm  | Excision  | Pain relieved |
| 23      | 27         | M   | Right | index  | subungual | 2 yrs                        | 5mm  | Excision  | Pain relieved |

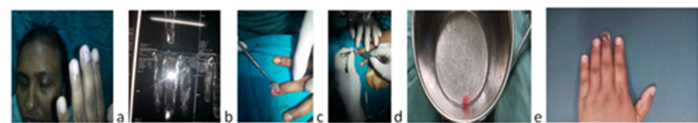
| Case no | Age (year) | sex | side  | Digit  | location  | Duration before presentation | Size | Treatment | Result        |
|---------|------------|-----|-------|--------|-----------|------------------------------|------|-----------|---------------|
| 24      | 48         | F   | Left  | Index  | subungual | 4 yrs                        | 5mm  | Excision  | Pain relieved |
| 25      | 46         | F   | Right | Ring   | subungual | 4yrs                         | 3mm  | Excision  | Pain relieved |
| 26      | 24         | F   | Right | Little | subungual | 3 yrs                        | 5mm  | Excision  | Pain relieved |
| 27      | 38         | F   | Left  | Ring   | subungual | 3yrs                         | 4mm  | Excision  | Pain relieved |
| 28      | 44         | M   | Right | Middle | subungual | 3yrs                         | 3mm  | Excision  | Pain relieved |
| 29      | 32         | F   | Right | Ring   | subungual | 3yrs                         | 4mm  | Excision  | Pain relieved |
| 30      | 34         | F   | Right | Ring   | subungual | 3 yrs                        | 4mm  | Excision  | Pain relieved |



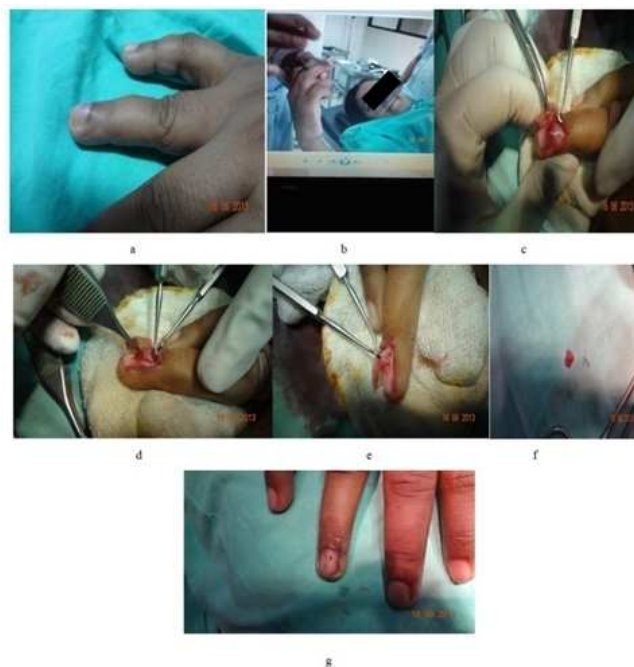
**Figure 1.** a. Pre operative image 22yrsfemale at right ring finger at sub ungualregion at radial border. b. pin point tenderness at lesional area c. MRI atring fingershowingwell defined mass beneath the nail plate. d. Per operative appearance. e. after removal of glomus tumor. f. post operative appearance at 10 days.



**Figure 2.** a. pre operative image of 50 yrsmale, glomustumor radial border at subungualregion of right index finger. b. Pin point tenderness atlesional area. C. MRI of right index finger. d. per operative appearence. e. after removal tumor. f. post operative appearance at one month



**Figure 3.** a Pre operative image of 36yrs female, glomus tumor at left middle finger at sub ungual region. b. MRI left middle finger c. per operative appeared. After removal of tumore. excised glomus tumor. f. Post operativeat 1 month with changes at pail plate.



**Figure 4.** a. Pre operative image of 25 yrs female, glomus tumor at subungual region Right ring finger. b. pin point tenderness at lesionalarea. cd. per operative appearance e. appearance after excision. f. excised tumor g. appearance after excision.

## 4. Discussion

It is difficult to diagnose the patient with glomus tumor from characteristic clinical findings and radiograph. Recently, HR-MRI has been developed to diagnose small lesion and its usefulness has been reported in diagnosis of glomus tumor in the finger tips which can be detected the mass as is ointence of the dermis of the nail bed on T1 weighted image and hyperintense on T2 weighted image [11-15]. They had a long history of suffering from onset to clinical diagnosis using HR-MRI which detected the mass at distal phalanx. Therefore HR-MRI is considered to be a usefulness method to diagnose glomus tumor in fingers. In all patients symptoms such as pain on touching and exposure to coldness disappeared after surgery and no recurrence was observed. Surgical excision and biopsy for glomus tumor is effective and necessary to confirm the diagnosis and relieve pain [15-18]. However it is important that surgeons understand the accurate localization of the tumor and meticulous surgical plan pre operatively in order to avoid recurrence and nail deformity [18].

Glomus tumor was first described by Wood 1812 and was named by Masson in 1924. [6]. The glomus cells are specialized smooth muscle cells derived, particularly concentrated around dilated vascular spaces. In addition, nerve fibers and mast cells may be present in increased numbers. The tumor is exquisitely sensitive to changes in temperature which leads to contraction of myofibrils. This results in an increase in intracapsular pressure transmitted by unmyelinated nerve fibers leading to perception of pain [19].

Glomus tumors most commonly affect patients in 3<sup>rd</sup> to 5<sup>th</sup> decades of life as also seen in our study. Although cases have been described in all age group. [20]. A female predominance has been reported previously [20], as was seen in our series as well.

The treatment of Glomus tumor is surgical. [1, 4, 21]

The average delay in diagnosis was 4 years in our series. The transungual approach for excision of glomus tumor is usually recommended [20, 9, 22, 21, 18] as it gives the best exposure if the lesion is completely subungual. Replacing the nail plate in its original position has been suggested to prevent nail deformities [1]. The main disadvantage reported with lateral approach is the lesser degree of exposure of the nail bed in subungual lesions, particularly in cases of very small tumor [6].

The dense fibrous tissue surround the mass forming pseudo capsule [23]. Based on its histological character the tumor can be completely removed as a whole if careful dissection is made through fibrous pseudo capsule. As such encapsulated tumor could 'pop up' from the cavity.

Early recurrence may occur within weeks to months of surgery and presumably reflex in adequate excision and Later recurrence (years) is probably the result development of new tumor [24].

## 5. Conclusion

Glomus tumors presents as painful lesions especially in colder weather in the finger tips. The diagnosis of sub ungual glomus tumor is largely clinical. Radiological examination include HR-MRI is useful in the diagnosis of patients with subungual glomus tumor and gives an excellent information in detecting the occult lesion. Transungual approach is a simple, safe and effective procedure which can reduce the chances of recurrence by allowing examination of entire sub ungual region. The alleviation of pain following surgery is quite gratifying both for patients and surgeon. There is no case of recurrence in this study and nail changes are minimal. Complete surgical excision offers the only prospect of complete cure.

## Ethical Issue

This topic was presented several times in Bangladesh society for surgery of the hand Conference (BDSSH CON) and in Bangladesh Orthopaedic Society annual Conference (BOS CON) 2016 and also in Management of Hand tumor, in Indian society for surgery of the Hand conference (ISSH CON 2019).

## Conflict of Interest

All the author do not have any possible conflicts of interest.

## References

- [1] Carroll RE, Berman AT. Glomus tumors of the hand. *J Bone Joint Surg Am* 1972; 54: 691-703.
- [2] Tang CYK, Tipoe T, Fung B. Where is the lesion? Glomus tumors of the hand. *Arch Plast Surg* 2013; 40: 492-5.
- [3] Mathew A. Glomangiomas: Are they rare tumours or rarely diagnosed? *Internet J Hand Surg* 2012; 3. [cited 2018 Oct 22]; 3 (2). Available from: <http://ispub.com/IJHS/3/2/13861>.
- [4] Rosner IA, Argenta AE, Washington KM. Unusual volar pulp location of glomus tumor. *Plast Reconstr Surg Glob Open* 2017; 5: e1215.
- [5] Kim DH. Glomus tumor of the finger tip and MRI appearance. *Iowa Orthop J* 1999; 19: 136-8.
- [6] Samaniego E, Crespo A, Sanz A. Key diagnostic features and treatment of subungual glomus tumor. *Actas Dermosifiliogr* 2009; 100: 875-82.
- [7] Baek HJ, Lee SJ, Cho KH, Choo HJ, Lee SM, Lee YH, et al. Subungual tumors: Clinicopathologic correlation with US and MR imaging findings. *Radiographics* 2010; 30: 1621-36.
- [8] Schiefer TK, Parker WL, Anakwenze OA, Amadio PC, Inwards CY, Spinner RJ. Extradigital glomus tumors: A 20-year experience. *Mayo Clin Proc* 2006; 81: 1337-44.

- [9] Tomak Y, Akcay I, Dabak N, Eroglu L. Subungualglomustumours of the hand: Diagnosis and treatment of 14 cases. *Scand J PlastReconstrSurg Hand Surg* 2003; 37: 121-4.
- [10] Montandon C, Costa JC, Dias LA, Costa FHAA, Costa ACM, Daher RT, et al. Subungualglomus tumors: Imaging findings. *Radiol Bras* 2009; 42: 371-41.
- [11] Drapé JL, Idy-Peretti I, Goettmann S, Guérin-Surville H, Bittoun J. 1996. Standard and high resolution magnetic resonance imaging of glomus tumors of toes and fingertips. *J Am AcadDermatol* 35: 550-555.
- [12] Hou SM, Shih TTF, Lin MC. 1993. Magnetic resonance imaging of an obscure glomus tumor in the finger tip. *J Hand Surg* 18B: 482-483.
- [13] Koç O, Kivrak AS, Paksoy Y. 2007. Subungualglomus tumor: magnetic resonance imaging findings. *AustralasRadiol* 51: B107-109.
- [14] Opdenakker G, Gelin G, Palmers Y. 1999. MR imaging of a subungualglomus tumor. *Am J Roentgenol* 172: 250-251.
- [15] Takemura N, Fujii N, Tanaka T. 2006. Subungualglomus tumor diagnosis based on imaging, *J Dermatol* 33: 389-393.
- [16] Carroll RE, Berman AT. 1972. Glomus tumors of the hand. Review of the literature and report on twenty-eight cases, *J Bone Joint Surg* 54A: 691-703.
- [17] Enzinger FM, Weiss SW. 1995. Perivascular tumors. In: *Soft tissue tumors*. 3rd ed. St. Louis: Mosby; p. 701-733.
- [18] Takata H, Ikuta Y, Ishida O, Kimori K. 2001. Treatment of subungualglomustumour. *Hand Surg* 6: 25-27.
- [19] Rohrich RJ, Hochstein LM, Millwee RH. Subungualglomus tumors: An algorithmic approach. *Ann PlastSurg* 1994; 33: 300-4.
- [20] Song M, Ko HC, Kwon KS, Kim MB. Surgical treatment of subungualglomus tumor: A unique and simple method. *DermatolSurg* 2009; 35: 786-91.
- [21] Acar E. Surgical treatment outcomes of glomus tumor of the finger. *Hand Microsurg* 2017; 6: 125-9.
- [22] Shin DK, Kim MS, Kim SW, Kim SH. A Painful glomus tumor on the pulp of the distal phalanx. *J Korean NeurosurgSoc* 2010; 48: 185-7.
- [23] Kim SH, Suh HS, Choi JH, et al. Glomus tumor: a clinical and histopathologic analysis of 17 cases. *Ann Dermatol* 2000; 12: 95-101.
- [24] Vasisht B, Watson HK, Joseph E, Lionelli GT. Digital glomus tumors: a 29-year experience with a lateral sub periosteal approach. *PlastReconstrSurg* 2004; 114: 1486e9.