

Pulmonary Cavitation Post COVID-19 Pneumonia: A Case Report

Arjun Kumar^{1,*}, Ayushi Sahu², Rahul Kumar Gupta¹, Manju Bala¹, Akhlesh¹, Avishek Layek¹

¹Department of Pulmonary Medicine and Critical Care, All India Institute of Medical Sciences, Rishikesh, India

²Department of Pulmonary Anaesthesiology, All India Institute of Medical Sciences, Rishikesh, India

Email address:

aknlnegi@gmail.com (A. Kumar), ayushisahu1311@gmail.com (A. Sahu), drrahulk08@gmail.com (R. K. Gupta),

drmanju2015@gmail.com (M. Bala), akhileshrajpoot855@gmail.com (Akhlesh), avilayek.nrsmc@gmail.com (A. Layek)

*Corresponding author

To cite this article:

Arjun Kumar, Rahul Kumar Gupta, Manju Bala, Akhlesh, Avishek Layek, Ayushi Sahu. Pulmonary Cavitation Post COVID-19 Pneumonia: A Case Report. *Advances in Surgical Sciences*. Vol. 9, No. 2, 2021, pp. 25-27. doi: 10.11648/j.ass.20210902.13

Received: July 17, 2021; **Accepted:** August 10, 2021; **Published:** October 12, 2021

Abstract: The coronavirus disease 2019 (COVID-19) is now rapidly spreading at a much faster rate than the first wave reported in December 2019. Computed tomography (CT) scans play crucial roles in the diagnosis of COVID-19 pneumonia where rRT-PCR test reported negative in strong clinical suspicion. Common chest radiological findings in COVID-19 are bilateral peripheral ground-glass opacities, consolidation, linear opacities and interstitial thickening. However, bilateral cavitory lung disease is a rare entity in COVID-19. Here, we present the case of a 62-year-old patient with severe COVID-19 pneumonia with initial rRT-PCR was negative for COVID-19 and who had atypical manifestations of the COVID-19 disease on a CT scan showing multiple cavitation with consolidation in the lungs. Special blood investigations showed raised blood procalcitonin, galactomannan, fibrinogen, D-dimer and BAL fluid pseudomonas aeruginosa growth and raised galactomannan. However, deteriorated on antibiotics along with antifungal drugs and supportive treatment. On high suspicion of viral pneumonia repeated rRT-PCR for COVID-19 came positive leading to fatal outcome.

Keywords: COVID-19, Pulmonology Cavitation, Computed Tomography, rRT-PCR

1. Introduction

Globally COVID-19 pandemic has caused over 2,880,726 deaths reported to the world health organisation (WHO). [1] In India alone more than 1270000 cases have been reported till 8th April 2021. [1] The COVID-19 virus spreads mainly via respiratory droplets during close contact from infected persons. Most of the cases usually are asymptomatic with mild fever and sore throat. It can affect any vital organs in the human body but lung is the most commonly affected organ leading to pneumonia and severe acute hypoxic respiratory failure leading to fatal outcomes. Radiology such as chest x-ray and computed tomography (CT) scans play vital roles in the diagnosis of severe COVID-19 pneumonia.[2] Most common chest CT abnormalities seen in patients with COVID-19 pneumonia are bilateral peripheral ground glass opacities (sub pleural locations), consolidations, air bronchogram, pneumothorax with or without pneumomediastinum, fibrosis, traction bronchiectasis,

reticular opacity with inter and intralobular septal thickening in the absence of any cavitation.[2-4] Other radiological findings bulla, cysts and cavitation in the lung are rare. [3-5, 6] Many times real-time reverse transcriptase polymerase chain reaction (rRT-PCR) for COVID-19 showed negative results before the final diagnosis was made. [7, 8] In such cases diagnosis of COVID-19 pneumonia relies on the typical features of COVID-19 pneumonia on chest CT scan. However, atypical features like cavities of COVID-19 disease on radiology may lead to misdiagnosis and delay in treatment line leading to fatal prognosis which may also increase the chances of spreading infection to other patients before actual diagnosis of COVID-19 is made. Atypical radiological manifestation of multiple cavitation as the presentation of COVID-19 pneumonia is rare and there are only few cases in literature reported multiple cavities in the lungs on a chest CTs as a sign of COVID-19. Here we present the case of a 62-year-old patient with severe COVID-19 pneumonia whose initial rRT-PCR was negative for

COVID-19 and who had atypical manifestations of the COVID-19 disease on a CT scan showing multiple cavitation with consolidation in the lungs.

2. Case Report

A 62-year-old female presented in hospital in the patient unit with complaints of dry cough and intermittent fever for five days. Patient had a history of loss of appetite and weight in the last three months. She was a non-smoker and had no history of tuberculosis in the past. Three months ago, a patient diagnosed Adenocarcinoma on histopathology immunohistochemistry and from the left lobe of liver segmentectomy tissue and she was asymptomatic until this episode. Her positron emission tomography (PET) computed tomography (CT) scan suggested right supraclavicular lymph node FDG uptake with no other organs involved in the body. On presentation her oxygen saturation was low (78%) under room air, tachycardia (120 beats per minute regular) and tachypnoea (34 per minute), blood pressure was low (90/60 mmHg). On chest auscultation bilateral coarse crepitations were present, no palpable lymphadenopathy and rest of the systemic examination were unremarkable. Her arterial blood gas showed severe type 1 respiratory failure and she was put on high flow oxygen via a non-rebreathing mask. Routine blood test revealed haemoglobin concentration of 10.2g/dl, platelet count of $206 \times 10^9/L$, leucocyte count of $12.8 \times 10^9/L$, D-dimer 3.19 mg/L, serum fibrinogen 689.3 mg/dL and procalcitonin was 0.37 ng/dl.

Initial oropharyngeal swab reverse-transcriptase polymerase chain reaction (RT-PCR) for COVID-19 was negative, contrast enhanced computed tomography (CECT) thorax with high resolution CT on presentation suggestive numerous cavitary lesions with surrounding consolidation in both lungs with associated soft tissue nodules and multifocal areas of consolidation Figure 1. Differentials include Septic emboli, atypical/fungal pneumonia. CT pulmonary angiography showed pulmonary thromboembolism in right lower lobe segmental branches. Her 2 D echocardiography was normal and no evidence of deep vein thrombosis in bilateral lower limbs. She was started on therapeutic dose low molecular weight heparin along with broad spectrum intravenous antibiotic and other supportive treatment. On special investigation for antineutrophil cytoplasmic antibodies (cANCA or pANCA), blood and urine cultures were negative. Fiberoptic bronchoscopy (FOB) was done and bronchoalveolar lavage (BAL) fluid was sent for diagnostic workup. Her BAL fluid showed growth of *Pseudomonas aeruginosa* sensitive to meropenem, cartridge based nucleic acid amplification test (CBNAAT), acid fast bacillus (AFB) for *Mycobacterium tuberculosis* was negative, cytology was negative for malignant cells. Blood and BAL fluid galactomannan was raised 2.34 and 4.2 ng/ml respectively. She was started on intravenous voriconazole and meropenem and linezolid along with other supportive therapy. On further deterioration of her clinical condition, she was admitted in intensive care unit (ICU) and put in non-invasive ventilation

support and ultrasound guided biopsy from lung lesion was done. In view of non-improving clinical condition repeat oropharyngeal swab for COVID-19 RT-PCR test was sent which came to be positive. She was shifted to COVID isolation ICU area where she further deteriorated and went into septic shock and she was intubated and started on dual inotropic support but she died within 12 hrs of intubation.

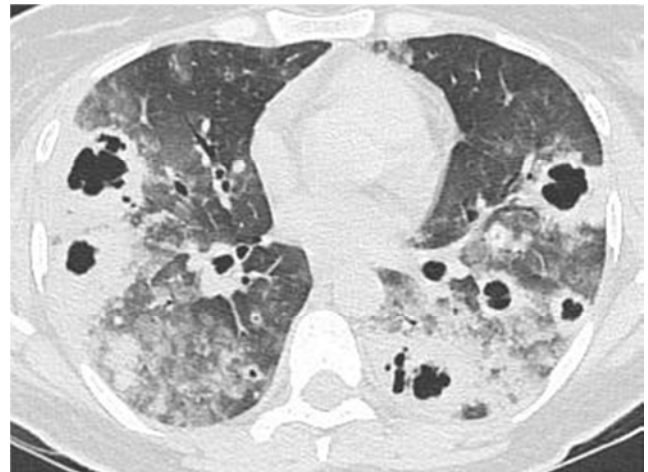


Figure 1. Both Lungs with Associated Soft Tissue Nodules and Multifocal Areas of Consolidation.

3. Discussion

Infection with COVID-19 virus can manifest as fever, sore throat and myalgia to severe pneumonia with acute hypoxic respiratory failure. Oropharyngeal swab rRT-PCR is a standard diagnostic test according to the WHO.[1] However, cases with low oropharyngeal viral shedding can lead to false negative rRT-PCR test for COVID-19 leading to misdiagnosis before the final diagnosis was made. [7, 8] As in this case initial rRT-PCR was negative for COVID-19. In such situations, a CT scan of the chest plays a very crucial role in the early diagnosis of COVID-19 pneumonia. [3-6] Typical chest CT abnormalities seen in patients with COVID-19 pneumonia are bilateral peripheral patchy areas of ground glass opacities (sub pleural locations), consolidations and air bronchogram. [2-7] However, other rare radiological findings in COVID-19 pneumonia are pneumothorax, pneumomediastinum, lymphadenopathy, pleural effusion, bulla, cysts and cavitation. [3-5]

In our case chest CT showed the patient had bilateral multiple cavitation with surrounding GGOs and dense consolidation. isolation for treatment, the majority of patients with COVID-19 pneumonia had their symptoms relieved and the laboratory test results returned to normal. A cavity is defined as an air-filled area of the lung in the centre of consolidation, mass or nodule. Cavities are present in a wide variety of infectious and non-infectious processes as a result of liquefaction of the necrotic portion of the lesion and the discharge of this necrotic material via the bronchial tree. It is uncommon for COVID-19 and other viral pneumonia infections to cause pulmonary cavitation. [7-9] In our case

we tried to rule out possible causes of lung cavities using both invasive and non-invasive methods including trans thoracic lung biopsy, fiberoptic bronchoscopy and ANCA antibodies (negative), blood galactomannan (elevated). BAL fluid detected *Pseudomonas aeruginosa* growth and elevated galactomannan. However, CT pulmonary angiography detected right lower lobe segmental pulmonary thromboembolism which can be a possible cause of unilateral lower lobe cavitation but difficult to justify bilateral cavitation. [10, 11] We are unable to speculate as to whether bacterial infection and/or invasive fungal coinfection may have contributed to the development of the cavities, or if the infections were opportunistic.

In a recent retrospective observational study of 689 patients with mild to severe COVID-19 pneumonia 1.7% (12/689) patients had cavity on CT chest at admission all admissions, and patients with severe COVID-19 lung disease had a poor prognosis.[6] In our case also patient unfortunately progress to refractory shock and died within one day after diagnosis of severe COVID-19 pneumonia. The lung cavity can further lead to detrimental complications like massive haemoptysis, abscess formation, sepsis, pneumothorax, pneumomediastinum, subcutaneous emphysema formation. Lung cavitation in the CT chest can probably be considered as the predictor of severe/end-stage COVID-19 disease.[12] Further larger studies are required to determine whether lung cavities in COVID-19 associated with poor prognosis and its importance in rRT-PCR negative COVID-19 suspect patients.

4. Conclusion

In conclusion pulmonary cavitation in post COVID-19 patients is not an uncommon entity. Multiple factors include secondary bacterial fungal and micro vascular thrombosis can lead to cavity formation in the COVID-19 patients which further increase the morbidity and mortality in these subset of patients. Hence patients of COVID-19 not improved with standard treatment and having cavities in lungs should search for etiology and appropriate treatment should be started to prevent fatal outcomes.

Author Contributions

Arjun Kumar: Collected patient data, drafted manuscript.

Ayushi Sahu, Avishek Layek, Manju Bala, Akhlesh: revised the manuscript.

Rahul Kumar Gupta: drafted and revised manuscript.

References

- [1] World Health Organization. Coronavirus disease 2019 (COVID-19) situation report. <https://www.who.int/emergencies/diseases/novel-coronavirus-2019/situation-reports>; accessed 8 April 2021).
- [2] Chinese Society of Radiology. Radiological diagnosis of new coronavirus infected pneumonitis: expert recommendation from the Chinese Society of Radiology (First edition). *Chin J Radiol* 2020; 54: 279–85.
- [3] Shi HS, Han XY, Jiang NC, et al. Radiological findings from 81 patients with COVID-19 pneumonia in Wuhan, China: a descriptive study. *Lancet Infect Dis* 2020; 20: 425–34.
- [4] Selvaraj V, Dapaah-Afriyie K. Lung cavitation due to COVID-19 pneumonia *BMJ Case Reports* CP 2020; 13: e237245.
- [5] Sun R, Liu H, Wang X. Mediastinal emphysema, giant bulla, and pneumothorax developed during the course of COVID-19 pneumonia. *Korean J Radiol* 2020; 21: 541–4. 10.3348/kjr.2020.0180 [PMC free article] [PubMed] [CrossRef] [Google Scholar].
- [6] Zoumot, Z., Bonilla, MF., Wahla, A. S. et al. Pulmonary cavitation: an under-recognized late complication of severe COVID-19 lung disease. *BMC Pulm Med* 2021; 24. <https://doi.org/10.1186/s12890-020-01379-1>.
- [7] Ai T, Yang Z, Hou H, Zhan C, Chen C, Lv W, et al. Correlation of chest CT and RT-PCR testing for Coronavirus disease 2019 (COVID-19) in China: A report of 1014 cases. *Radiology*. 2020; 296 (2): E32–40.
- [8] Xie XZ, Zhong Z, Zhao W, et al. Chest CT for typical 2019-nCoV pneumonia: relationship to negative RT-PCR testing. *Radiology* 2020; DOI: 10.1148/radiol.2020200343.
- [9] Yang W, Sirajuddin A, Zhang XC, et al. The role of imaging in 2019 novel coronavirus pneumonia (COVID-19). *Eur Radiol* 2020; DOI: 10.1007/s00330-020-06827-4.
- [10] Ajlan AM, Ahayd RA, Jamjoom LG, Alharthy A, Madani TA. Middle East respiratory syndrome coronavirus (MERS-CoV) infection: chest CT findings. *AJR Am J Roentgenol*. 2014; 203 (4): 782–7.
- [11] Koo HJ, Lim S, Choe J, Choi S-H, Sung H, Do K-H. Radiographic and CT features of viral pneumonia. *Radio Graphics*. 2018; 38 (3): 719–39. <https://doi.org/10.1148/rg.2018170048>.
- [12] Wong KT, Antonio GE, Hui DSC, et al. severe acute respiratory syndrome: radiographic appearances and pattern of progression in 138 patients. *Radiology*. 2003; 228 (2): 401–6. <https://doi.org/10.1148/radiol.2282030593>.